

Surface architecture of the mouth cavity of *Pagellus affinis* (Boulenger, 1888)

Kamal Ahmed Baaom*

Manal Haj Obbed*

Abstract

The topological characteristics of the mouth cavity of the carnivorous fish *Pagellus affinis* was studied by using light microscope. The results revealed that all the teeth of *P. affinis* are pointed and canine-like, papilliform teeth present on the premaxillae and the anterior regions of the dentaries are associated with seizing, grasping and holding of prey. The morphology and distribution of different taste buds of *P. affinis* were predominantly localized at the anterior and tongue regions of the mouth cavity. Two types of taste buds are elevated from the epithelium at different levels, which may be useful for ensuring full utilization of the gustatory ability of the fish, detection and analyzing of taste substances, as well as for assessing the quality and palatability of food, during its retention in the mouth cavity. Observations of the surface architecture of the mouth cavity of *P. affinis* are discussed within the context of feeding and habitat preferences as well as ecomorphological adaptation of the species.

Keywords: *Pagellus affinis*, surface architecture, mouth cavity, taste buds.

Introduction:

The spridae are widely distributed in tropical to temperature seas [4]. *Pagellus affinis* was belonged to Sparidae which commonly called sea breams, are represented by 29 genera and 100 species [17]. The mouth shapes and buccal cavities of fishes are a good an important component of the digestive tract. It may be involved in the seizure, the selection of food, rejection of undesirable items ingested by fish and the predigesting preparation of food. Among species, Buccal or Oropharyngeal cavity structure shows great plasticity and structural adaptability for the exploitation of different food items [12; 11; 23; 9 and 1]. The mouth cavity has been described using light microscopy in *Oryzias latipes* [8] *Oncorhynchus rhodurus* [14], *Tribolodon hakonensis* [15] and *Barbus bynni*, *Chrysichthys auratus*, *Mormyrus kannume* and *Synodontis schall* [1]. In any vertebrate species, gustation contributes to the acceptance or rejection of potential foods for survival, since taste buds primarily function in the feeding behavior to detect chemical from preys. Teleosts are reported to have the most taste buds of all vertebrates. Carnivorous fishes are endowed with taste buds, not only in the oral cavity including gill regions, but also on the lips, barbells, and external skin surface [7; 18; 6 and 22]. Palatability and taste are two terms often used interchangeably which are determined mostly by the chemical characteristics of the food, although its physical properties can also affect the

acceptability and final ingestion or rejection of the food [20]. Fish have been often employed as a model for taste research, as they show a higher sensitivity (estimated thresholds for the most potent substances are less than 10^{-9} M, to tastants than mammals [13]. Taste buds are secondary sense organs of the gustatory chemosensory system, it may be useful in assessing the palatability of the food and decide whether to swallow or spit it out [23]. The present study describes the morphology and distribution of different taste buds that located on the epithelium surface of the mouth cavity of *P. affinis*. The taste buds may be useful in assessing the palatability of the food and decide whether to swallow or spit out.

Materials and Methods:

Arabian Pandora (*Pagellus affinis*) were collected from the fishermen at Mukalla Markets (Gulf of Aden) (Fig. 1). These were brought to the laboratory of Biology, Faculty of science, Hadhramout University. The shape, direction, position of mouth and the distribution of teeth in the different regions of buccal cavity are observed and recorded. For the measurement of head, 10 specimens for each species are examined and the following measurements are taken: (Head length (HL) in cm, Head height (Hh) in cm, Mouth opening height (M.O.H) in cm, Mouth opening width (M.O.W) in cm and Mouth tube length (Tu L) in cm. Data have been represented in the form of histograms using Microsoft office excel. The buccal cavity was opened, cleaned carefully in a physiological saline solution and fixed in 10 % neutral buffered formalin. Dehydration, cleared and put in paraffin wax. Samples were sectioned (6-8 μ

* Department of Biology, Faculty of Science Hadhramout University. Received on 2/4/2017 and Accepted for Publication on 8/10/2018

thick) and stained with the counter stain haematoxylin and eosin (H&E) according to [2] and [19]. The sections were examined under the routine light microscope and photographs taken routine photo microscopic attachment. Pictures of the mouth, jaws and pharyngeal teeth were taken by digital camera model (Canon, Power Shot A480; 3.3X).

Results:

Morphometrical Study:

In the present work the mouth is forward, terminal with M.O.H was 2.92 ± 0.36 cm and M.O.W. was 1.87 ± 0.13 cm, having two rows of teeth. TL/HL ratio was 0.65 ± 0.10 . Different measurements is measured and listed in Table (1). The buccal cavity of *P. affinis* is spacious and opens anteriorly through a wide transverse mouth, which is bordered by the upper and the

lower lips. The mouth cavity is divided into two regions – the dorsal roof and the ventral floor. The roof and the floor of the mouth cavity comprised antero-posteriorly, an upper jaw with premaxillary teeth and vomerine teeth, respectively. Superior and inferior pharyngeal teeth are observed, the last one is found near the gill arch (Figs. 1, 2 & 3).

Histological Studies:

Optical microscope micrographs showed that abundant of taste buds on upper and lower lips of *P. affinis*. Distribution of different taste buds bears pointed canine-like and around between most of the surface of epithelial of the mouth cavity (Figs. 4, 5, 6 & 7). A scattered residue of mucus cells of varied dimensions are observed (Fig. 4).



Figure 1: The mouth of *Pagellus affinis*

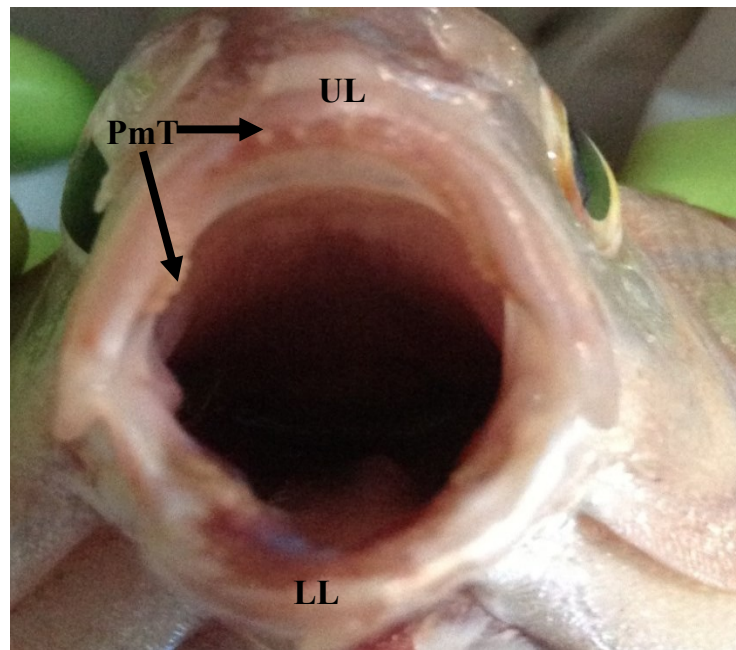


Figure 2: Photograph the mouth of *P. affinis*. UL: upper lip, PmT: premaxillary teeth, LL: lower lip

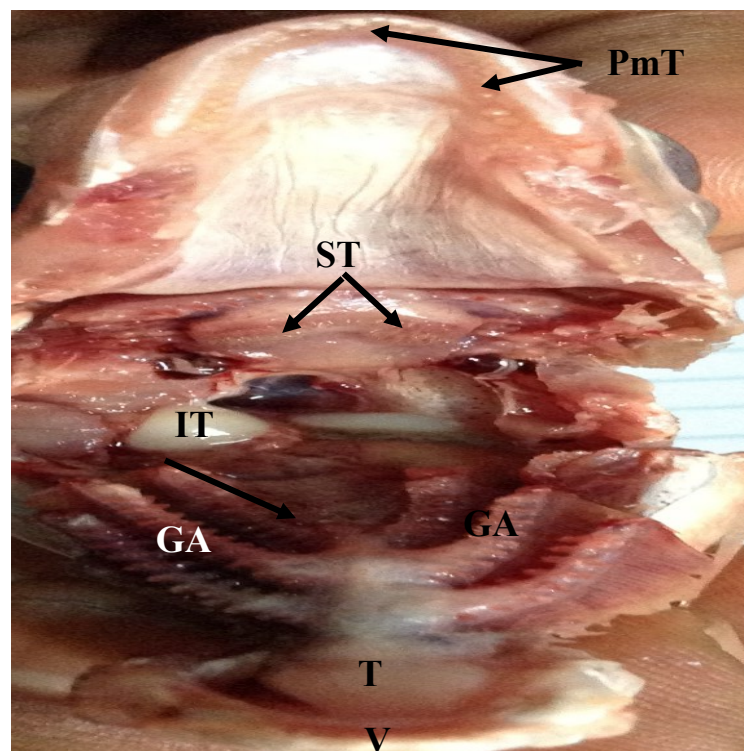


Figure 3: Photograph showing the morphology of the roof and the floor of the mouth cavity of *P. affinis*. PmT: premaxillary teeth, V: vomerine teeth, T: tongue, ST: superior pharyngeal teeth, IT: inferior pharyngeal teeth and GA: gill arch

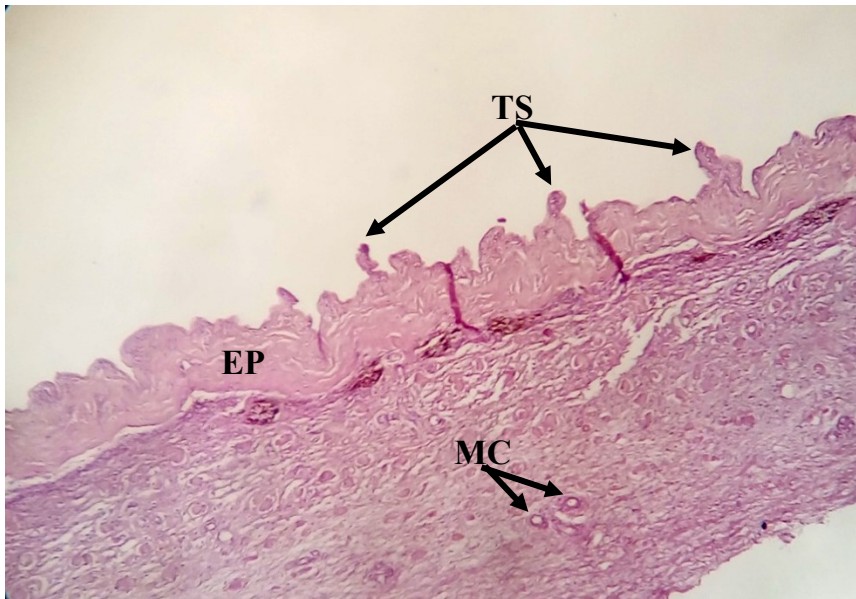


Figure 4: Photomicrograph of transverse section of upper lip of *P. affinis* showing: TS: taste buds are elevated and located on epithelial protrusion, EP: epithelium surface and MC: mucus cells (H&E, X 100)

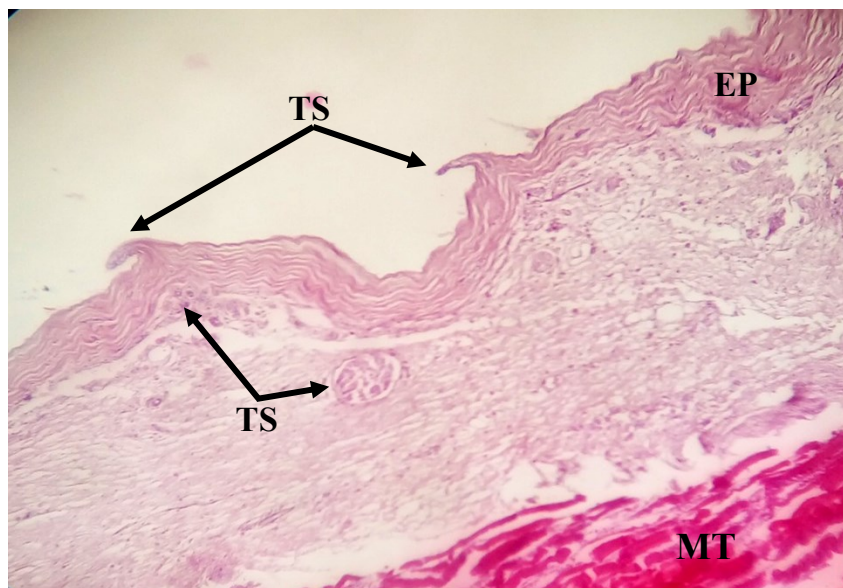


Figure 5: Photomicrograph of transverse section of lower lip of *P. affinis* showing: TS: taste buds elevated and located on epithelial protrusion, EP: epithelium tissue and MT: muscular tissue (H&E, X 100).

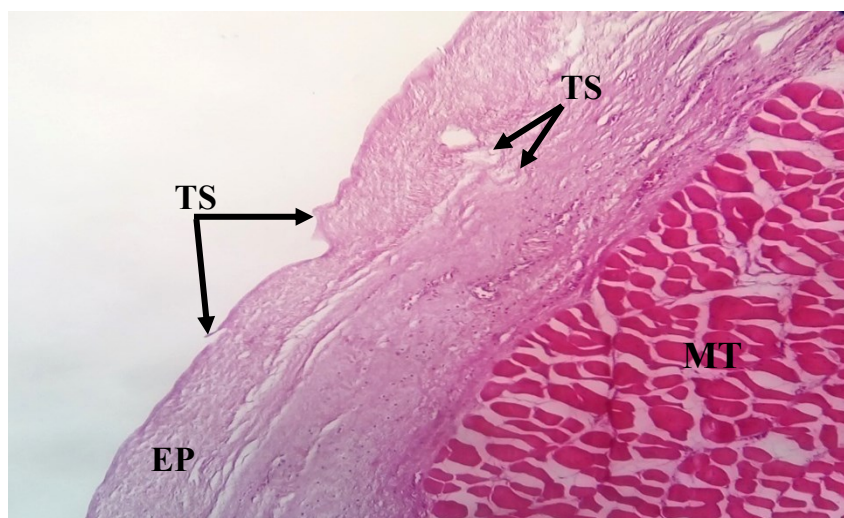


Figure 6: Photomicrograph of transverse section of the surface architecture of roof of the mouth cavity of *P. affinis* showing: TS: taste buds, EP: epithelium tissue and MT: muscular tissue (H&E, X 100)

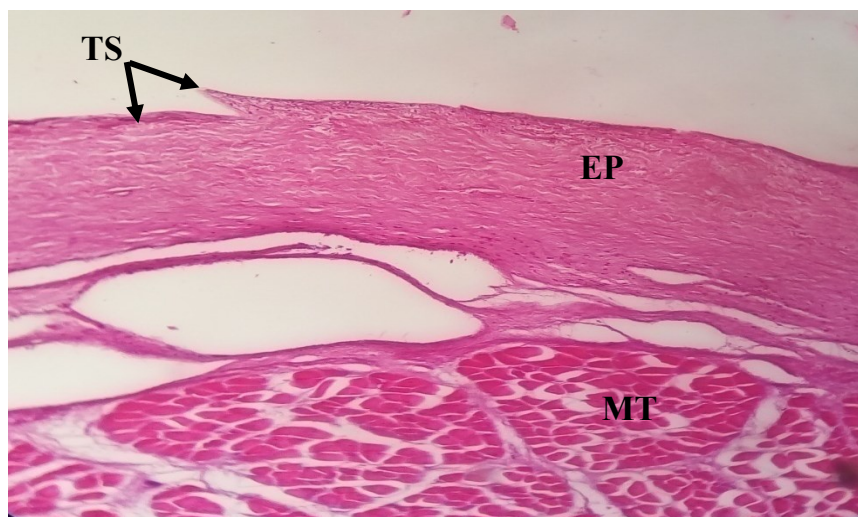


Figure 7: Photomicrograph of transverse section of the surface architecture of floor of the mouth cavity of *P. affinis* showing: TS: taste buds, EP: epithelium tissue and MT: muscular tissue (H&E, X 100)

Discussion:

In *Pagellus affinis*, the position and direction of mouth is suitable for capturing and obtaining food, its terminal and forward directed so facilitate the process of predation and indicate the predatory nature of fish under investigation, this result agree well with that recorded by [5 and 10]. The character of dentition is a clue to the fish's feeding habits and the kind of food it consumes [16]. Carnivorous *P. affinis* has pointed canine-like teeth; this type of teeth does a good job of grasping and piercing. In agreement with our results, [20] studying the teeth of *Atherion elymus*;

[23] studying the teeth of carnivorous in *Rita rita*; [9] studying the teeth of carnivorous *Bagrus docmak* and the omnivorous *Claris gariepinus*; [1] studying the teeth of herbivorous *Barbus bynni*, carnivorous *Chrysichthys auratus* and *Mormyrus kannume* and omnivorous *Synodontis schall* and [10] studying the teeth of carnivorous *Epinephelus chlorostigma*. Differences described for dentition and distribution of taste buds on the epithelial cells at different regions of the roof and floor of the mouth cavity of fishes could considered as adaptation to various food preferences and feeding behavior of fish [23; 9; 1; 6; 3; 22 and 21].

References:

- 1- Baaom, K. A. (2012). Structure of the digestive tract of some Nile Fishes in relation to their food and feeding habits: a light and electron microscope study. P. Dh. Thesis, Assiut University, Assiut – Egypt.
- 2- Bancroft, D. and Stevens, A. (1982). Theory and practice of histological techniques. Churchill Livingstone, Edinburgh, London, Melbourne.
- 3- Carla J. L. Atkinson, Kyle J. Martin, Gareth J. Fraser, and Shaun P. Collin. (2016). Morphology and distribution of taste papillae and oral denticles in the developing oropharyngeal cavity of the bamboo shark, *Chiloscyllium punctatum*. The Company of Biologists Ltd | Biology Open 5, 1759-1769 doi:10.1242/bio.022327.
- 4- Froese, R. and Pauly, D., (2013). Fish Base. Version 12/2013.[Online] Available at: <http://www.fishbase.org>. Accessed 17 December 2013.
- 5- Fugi, R., Agostinho, A. A. and Hahn, N. S. (2001). Trophic morphology of five benthic-feeding fish species of a tropical floodplain. Rev. Bras. Zool. 61(1).
- 6- Gamal, A.M.; Elsheikh E.H. and Nasr, E.S. (2012). Morphological adaptation of the buccal cavity in relation to feeding habits of the omnivorous fish *Clarias gariepinus*: A scanning electron microscopic study. The Journal of Basic & Applied Zoology (2012) 65, 191–198.
- 7- Gomahr, A., Palzenberg, M. and Kotrschal, K. (1992). Density and distribution of external taste buds in Cyprinids. *Environmental Biology of Fishes*, 33,125-134.
- 8- Hamed, M. S.; Gahr, O. M. and Ghoneum, M. M. (1984). Development and distribution of taste buds in *Oryzias latipes* and their functional significance. Japan. J. Ichthyol., 31: 335- 337.
- 9- Harabawy, A. S. A. ; Mekkawy, I. A. A. ; Mahmoud. U. M. ; Abdel- Rahman. G. H. and Khidr. B. M. (2008). Surface architecture of the oropharyngeal cavity and the digestive tract of *Bagrus docmak* (Forsskal, 1775) and *Clarias gariepinus* (Burchell, 1822) (Teleostei) from the Nile River: A scanning electron microscope study. *Zoology Department, Faculty of Science, Assiut University, Assiut, Egypt*.
- 10- Hassan, A. A. (2013). Anatomy and histology of the digestive system of the carnivorous fish, the brown-spotted grouper, *Epinephelus chlorostigma* (Pisces; Serranidae) from the Red Sea. Life Science Journal. 10(2): 2149-2164.
- 11- Horn, M. H. (1998). Feeding and digestion. In : EVANS, D. H. (ed), *The Physiology of Fishes*. CRC Press, Boca Raton, New York : 43- 63.
- 12- Kapoor, B. G. and Khanna. (1994). The alimentary canal of teleosts: A brief survey of structure and function. In: SINGH, H. R. (ed), *Advances in Fish Biology* Vol. I. Hindustan Publishing corporation, Delhi: 12- 24.
- 13- Kasumyan, A. O. and Døving, K. B. (2003). Taste preferences in fishes. Fish. 4, 289-347.
- 14- Komada, N. (1993). Distribution of taste buds in the Oropharyngeal cavity of fry and fingerling Among salmon, *Oncorhynchus rhodulus*. Japan. J. Ichthyol., 40: 110- 116.
- 15- Komada, N. (1994). Distribution of Taste Buds in the Oropharyngeal Cavity of Larval and Juvenile Stages of the Cyprinid Fish, *Tribolodon hakonensis*. *Japan. J. Ichthyol.* 41(3): 307-311.
- 16- Monsefi, M., Gholami, Z. and Esmaceli, H. (2010). Histological and morphological studies of digestive tube and liver of the Persian tooth-carp, *Aphanius persicus* (Actinopterygii: Cyprinodontidae). IJBS Journal of Biology, 69(1): 57-64.
- 17- Randall, J.E. (1995). Coastal Fishes of Oman. University of Hawaii Press, Honolulu, Hawaii, Pp. 227.
- 18- Reutter, K., Boudriot, F. and Witt, M. (2000). Heterogeneity of fish taste bud ultrastructure as demonstrated in the holosteans *Amia calva* and *Lepisosteus oculatus*. Phil Trans R Soc Lond B 355, 1225-1228.
- 19- Ribeiro, L. ; Sarasquete, C. and Dinis. M. T. (1999). Histological and histochemical development of the digestive system of *Solea senegalensis* (Kaup, 1858) larvae. Aquaculture 171: 293-308.
- 20- Sire, J. Y. and Allizard, F. (2001). A fourth teleosts lineage possessing extra-oral teeth: The genus *Atherion* (teleostei; Atheriniformes). Europ. J. Morph., 39: 295-305.
- 21- Sofia Morais (2017). The Physiology of Taste in Fish: Potential Implications for Feeding Stimulation and Gut Chemical Sensing. Reviews In Fisheries Science & Aquaculture vol. 25, no. 2, 133–149.
- 22- Wang, C. A.; Ma, J. Z.; Xu, Q. Y.; Yin, J. S.; Li, J. N.; Wang, L. S.; Zhao, Z. G.; Luo, L. (2016). The development of pharyngeal taste buds in *Hucho taimen* (Pallas, 1773) larvae, Iranian Journal of Fisheries Sciences 15(1) 426-435.
- 23- Yashpal, M.; Kumari, U.; Mittal, S. and Mittal, A. K. (2006). Surface architecture of the mouth cavity of carnivorous fish *Rita rita* (Hamilton, 1822) (Siluriformes, Bagridea). Belg. J. Zol., 136 (2): 155-162.

التركيب السطحي للتجويف الفمي في سمكة الحميرا (Boulenger, 1888) *Pagellus affinis*

منال حاج عبد

كمال أحمد باعوم

الملخص

في هذا البحث تمت دراسة خصائص البطانة السطحية للتجويف الفمي لسمكة الحميرا *P. affinis* باستخدام المجهر الضوئي. أوضحت النتائج أن جميع أسنان السمكة قيد الدراسة مدببة شبه كلابية، إن جميع الأسنان الحلمية الموجودة على المناطق الأمامية من التجويف تتناسب مع الاستيلاء والإمساك بالفريسة. تم تحديد موقع مورفولوجيا وتوزيع براعم التذوق المختلفة للسمكة قيد الدراسة، في الغالب تتمركز في المناطق الأمامية واللسان من تجويف الفم. وجدت نوعان من براعم التذوق والتي تكون في مستويات علوية مختلفة من الطبقة الطلانية (الظهارية)، والتي قد تكون مفيدة لضمان الاستفادة الكاملة من القدرة الذوقية للسمكة. كشفت هذه الدراسة مدى ملائمة بنية سطح تجويف الفم في السمكة مع طبيعة غذائها والتكيفات الشكلية البيئية.

كلمات مفتاحية: *Pagellus affinis* ، الحميرا، البطانة السطحية، التجويف الفمي، براعم التذوق.