

Unilateral Vocal Fold Paralysis in Adults: Etiological Factors in Yemen

Ali Obaid Muthanna*

Abstract

Unilateral vocal fold paralysis is common finding in otolaryngology practice. Various etiologies known to cause this condition are neck surgery, cancer, neck trauma, neurological disorders and idiopathic. The aim of this study was to determine the possible etiologies of unilateral vocal fold paralysis among adult patients. A prospective hospital based study was conducted at OtoLaryngology Department, at Al-Thawra Teaching Hospital, Sana'a, Yemen, during the period January 2015-June 2018. Patients with unilateral vocal fold paralysis were enrolling in this study. All patients underwent to history, clinical examination, laboratory investigations, and radiological studies. A total of 80 patients with unilateral vocal fold paralysis, males (73.6%), females (26.4%). The age ranged from 18 to 80 years. Peripheral causes in (93.7%) and central causes only in (6%) patients. Idiopathic (32.5%), malignancy (31.2%), trauma (21.2%), TB (7.5%). Left vocal fold paralysis was the most findings. Idiopathic was the most common cause followed by malignancies and trauma. Regarding position of the vocal fold paramedian position was found in (87.5%) patients while lateral position was in (12.5%). Thyroidectomy continues to be the single most surgical procedures responsible for unilateral vocal fold paralysis.

Key words: unilateral vocal fold paralysis, recurrent laryngeal nerve, etiology, thyroidectomy.

Introduction:

Unilateral vocal fold paralysis (UVFP) is defined as immobility of the vocal cord due to disruption of the motor nerve supply the larynx [8]. Various etiologies known to cause this condition are neck surgery, cancer, trauma, neurological disorders and inflammatory diseases [29]. Unilateral paralysis of the intrinsic laryngeal muscles preventing the vocal fold on affected side adduction to the midline lead to severe breathy or whispered air wastage [10]. Paralysis of recurrent laryngeal nerve (RLN) due to either surgical, iatrogenic injury or extra-laryngeal malignancies at any point along its course from the jugular foramen to mediastinum [6,27,37]. The patients are presenting with hoarseness of voice, aspiration, and shortness of breathing [11].

However, many of patients are clinically asymptomatic and the presence of UVFP may be only incidentally detected. In many such asymptomatic cases, a slow-growing malignancy with secondary involvement of the vagus or RLNs may result in computed tomography imaging findings that presented the clinical manifestations of VFP [7,22]. Trauma, cancer and surgery are the most common causes of vocal fold paralysis. Nevertheless some cases are associated with idiopathic causes. For this reason, in case of vocal cord paralysis, the actual effect should be observed in detail [17,32]. In ascertaining the cause, the physician needs to differentiate between central and peripheral lesion, as well as

unilateral versus bilateral [8].

The aim of this study is to determine the possible etiologies of UVFP in adult patients.

Subjects and Methods:

Prospective a hospital based descriptive study was carried out in the Department of OtoLaryngology, Head and Neck Surgery, Al-Thawra Teaching Hospital, Sana'a, Yemen among adult patients with unilateral vocal fold paralysis during the period January 2015 and June 2018. A total of 80 patients with unilateral vocal fold paralysis were enrolled in this study. A detailed history was taken of each patient. A complete clinical examination of each patient also performed to detect the causes of the lesion. Each patient was examined endoscopy and radiology. All patients are examined by flexible endoscopy. A high resolution CT imaging of the neck, brain and chest was also performed for each patient. We excluded children, patients with cancer larynx and cricoarytenoid joint fixation. All files were reviewed and following information was recorded.

T B, cases were diagnosed at medical department, they were on anti TB drugs and referred to our department for ENT evaluation, while cancer cases diagnosed by biopsy and histological study.

Patient's age, sex, presenting feature and causes of vocal fold paralysis. If all procedures are performed and no etiology is found, the patients with vocal fold paralysis is placed in the "idiopathic" category.

Statistical analysis:

The data was checked for completeness, coded then entered into computer by Statistical package for social sciences. Obtained data was analyzed

* Assitant prof. of Animal physiology Department of Biology, College of Sciences, Hadhrumout University, Yemen. Received on 13/7/2020 and Accepted for Publication on 16/11/2020

using descriptive statistical tools (frequencies and percentages). Finally the data was presented in tables and graphs by using computer applications.

The study was approved by Ethic Board of the Department of OtoRhioLaryngology , Head and Neck Surgery. Informed consent was obtained from each patient.

Results:

Out of 80 patients have unilateral vocal fold paralysis studied, 59 (73.6%) were male and 21 (26.4%) were female. Participants' the age ranged from 18 to 80 years. The patient's symptoms shows

in (Table 1) where change the voice was found in all patients , breathy voice was found in 40 patients (50%), aspiration and coughing occurred in 30 patients (37.5%). The left side UVFP was 58 (72.5%) of the patients, while right side affection was 22 (27.5%) of the patients. Peripheral causes were in 75 (93.7%) of patients while central causes only in 5 (6.3%) patients.. and central causes in 5(6.3%) patients. Regarding position of the vocal fold paralysis, paramedian position was found in 70 (87.5%) patients, while lateral position was occurred in 10 (12.5%) patients, one of them due to chest lesion.

Table 1.Symptoms among study participants (N=80)

.Symptoms	NO	%
Hoarseness of voice	80	100
Breathy voice	40	50
Aspiration	30	37.5
Cough	30	37.5
Dysphagia	12	15
Difficulty breathing	8	10
Stridor	7	8.8

Causes of unilateral vocal fold paralysis shown in table (2) and figure (1) shown the main etiological groups. The main cause of unilateral vocal fold paralysis in our study was idiopathic

26 cases (32.5%), followed by malignancy 25 cases (31.2%), neck trauma, either surgical or accidental 17 cases (21.5%), and less rate caused by Guillain^s Barre syndrome one case (1.3%).

Table 2 .Causes of unilateral vocal fold paralysis among participants (N=80)

Causes	NO.	%
Idiopathic	26	32.5
Malignancy	25	• Thyroid 8
		• Pyriform fossa 5
		• Nasopharynx 5
		• Oesophagus 4
		• Lung 3
Trauma	17	▪ Thyroid 7
		▪ Neck 5
		▪ Cardiac 5
TB	6	7.5
Central (3 Ich,2 cancer)	5	6.0
Guillain-Barre syndrome	1	1.3
Total	80	100

.Ich= intracranial hemorrhage.

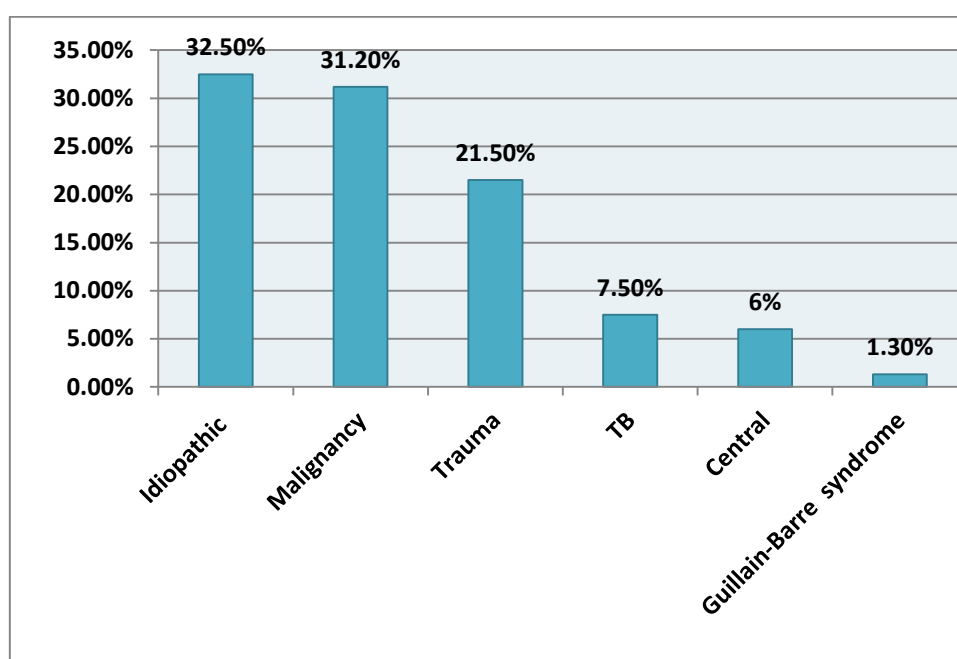


Figure 1: Causes percentage of unilateral vocal fold paralysis

Discussion:

Unilateral vocal fold paralysis occurs due to the damage of recurrent laryngeal nerve or vagus nerve which innervate the larynx. Patients present with breathy sound because of incomplete closure of the vocal cords. However, they may complaint of aphonia or shortness of breath [9,13] Recurrent laryngeal nerve paralysis (abductor paralysis of the larynx) may occur with left RLN paralysis more than right side. This type of lesion results in paralysis of all the intrinsic muscles of the larynx except the cricothyroid muscle which is innervated by the superior laryngeal nerve [4]. The left RLN is more vulnerable to injury than the right, because the left RLN course is longer [13,3]. In our study, we found the left side paralysis in (72.5%) and right side (27.5%) this result is similar to published studies [6,16].

Regarding the position of vocal fold, we found in the paramedian position in (78.5%) and in the lateral position in (12.5%). The patients with RLN paralysis were presented with paramedian position of paralyzed vocal folds, while the lateral position was found when the causes located in the base of the skull or intracranial due to affection of the superior laryngeal nerve and recurrent laryngeal nerve.

This results consistent with previous studies[14,4]. One case suffering of cancer lung was presented

with the left vocal fold paralysis in the lateral position. Howard [13] reported that clinically it is not uncommon

to see patients with intrathoracic lesion (which produce a pure recurrent palsy) with paralyzed vocal cord in the lateral position. Purported explanations for this are stretching of the nerve by the intrathoracic lesion thus pulling the vagus nerve down from the skull base and injuring the superior laryngeal nerve and possible retrograde atrophy of the vagus nerve to the nucleus ambiguus. Hoarseness of voice, breathy voice, aspiration, and cough were common presenting symptoms. Aspiration was occurred because of loss and disordered cough reflex. This results is similar to the previous studies [11,2], which reported that hoarseness of voice, intermittent stridor, breathy voice and aspiration. The patients that suffering of pyriform, esophageal, and advanced thyroid cancers, complaining of dysphagia (15%) in addition to respiratory symptoms we believed that caused by pressure effect of the mass and invasion of RLN by cancers. Our findings are consistent with those reported by Kayanagi, et al.[16], Myssonrek [20], Ryu et al. [28], where they suggested that these symptoms are due to compression of adjacent structures by the mass and/ or invasion of the RLN by malignant. UVFP has multiple etiologies, such as tumors, trauma, mechanical

dysfunction, or central nervous system dysfunction; it may also be a sequelae of extensive thoracic surgical treatment or thyroidectomy [33]. Idiopathic UVFP was the most common cause in our study, occurred in (32.5%) of cases. Incidence of idiopathic UVFP in previous studies were ranged from 18. to 33.3%. Urguhart and Luis [33], reported that (18.1%) of cases due to idiopathic, Al-khtoum et al. [1], found idiopathic in (18.9%) of cases, Senniappan et al. [30], reported that (19.2%) of cases due to idiopathic, while Jayanthy et al. [15] reported that (42.1%) of cases were due to idiopathic causes. There is variation in the incidence of idiopathic ULVF paralysis between different studies, this may be due to follow up and methods of investigations of cases. With recent improved imaging techniques, causative reason for vocal fold paralysis is often identified, resulting in decrease in the incidence of cases labeled as "idiopathic" after clinical examination (25%). Malignant neoplasm was second cause of UVFP in our study (31.2%) of cases. The most of them due to thyroid malignant (32%), followed by pyriform fossa, and nasopharynx (20%) for every area, esophagus and lung cancers had been found as causes of UVFP [26].

Malignant neoplasm has been as the most common cause of extralaryngeal UVFP [2]. Neoplasms of the thyroid, esophagus, mediastinum and the lung are not infrequently complicated by recurrent laryngeal nerve paralysis [1]. Previous studies found the most common malignancy causing UVFP originated from the lung [27,36]. Varghese et al. [32] found the commonest cause for unilateral fixation of vocal cord is its paralysis due to damage to RLN or vagus nerve due to malignant infiltration.

Traumatic causes found in (21.3%) of cases in our study, post-thyroidectomy UVFP was found in (41.2%) of traumatic cases. Thyroidectomy was the most individual surgical procedure responsible for iatrogenic UVFP. But the incidence of non-thyroidectomy surgeries, neck and cardiac trauma was (58.8%). The results of our study consist with other published studies, Rosenthal et al. [27] reported that thyroidectomy caused (34%) of iatrogenic UVFP, non-thyroidectomy trauma caused (66%) of VFP, Jayanthy et al. [15] reported that thyroidectomy was caused (40.7%), and non-thyroidectomy (59.9%).

However, two studies by Ko et al. [17] and Srirompoton et al. [31] have reported that the incidence of thyroidectomy that leads to UVFP was more than non-thyroidectomy trauma (neck

trauma and cardiac surgery), Rosenthal et al. [27] found that among non-thyroidectomy, anterior cervical spine surgery (15%), and cardiac surgery (9%), Jayanthy et al. [15] reported that (5.9%) of UVFP caused by cardiac surgery. This result is less than our results. Neck non-surgical trauma in our study, found in (29.4%) of cases due to gun-shot and stab wound, where these types of trauma are common in our country, so it's higher than that reported in other studies [15,12]. TB chest estimated among (7.5%) of cases in our study, investigating the causes of RLN paralysis, malignancies and tuberculosis should be considered in developed countries and in immigrants of the developed industrialized countries [19]. Fibrosis in chronic pulmonary tuberculosis in upper lobes and scar tissue may affect the RLN [25]. Damaged RLN may be due to lymph node compression and mediastinal fibrosis [9,24]. Vocal cord paralysis to intrathoracic pathology in tuberculosis may be caused by three possible mechanisms, a. Enlarged caseating mediastinal lymph nodes compressed RLN. b. Entrapment of the RLN in mediastinal fibrosis.

C. Stretching of the nerve owing to retraction of the upper lobe bronchus towards the upper in the case of apical fibrosis [25]. In current study, Guillain-Barre syndrome (GBS) was found in (1.3%) of cases.

GB syndrome, considers as very rare cause of UVFP unilateral [35]. Central causes of UVFP occurred in (6%) of our patients, three patients due to cerebro-vascular accidents, and two patients secondary to intracranial cancer. Previous studies [15,12] reported (12.4%) and (15%) UVFP due to central causes, these were double our results. The previous studies patients were old age above 50 years (48.3%), in our study, the old patients above 50 year were (20%) only, this may be the reason for difference in these results. Novel intraoperative nerve monitoring (IONM) for laryngeal nerve is being developed and may reduce the risk of UVFP following thyroid surgery [21]. More effective application of IONM is reasonable in patients with high risks [5]. The number of UVFP cases may be overestimated because of some patients may have malignancy-related UVFP before surgery, which remained undiagnosed because of their silent clinical presentation. Preoperative assessment of vocal fold should be carried out in the patient undergoing thyroid surgery [23].

Today it is possible for the clinician to utilize the information obtained from electrodiagnostic method

and postoperative laryngeal electromyography, to characterized nerve injury and predict temporal and function results of healing process. It is important to do so in order to be prepared for additional, intervention, such as voice therapy, medicalization, or regeneration / re-innervation therapy [5,18].

Conclusion:

Unilateral vocal fold paralysis has got a variable etiology. Idiopathic was the most common cause followed by malignancies, and trauma.

Thyroidectomy continues to be the single most common surgical procedure responsible for unilateral vocal fold paralysis. For this reason, pre and postoperative laryngoscopy should be considered in all surgeries with potential risk for recurrent nerve paralysis to reduce the postoperative morbidity. However, understanding the etiology of vocal fold paralysis should play a significant role in prevention and management of paralysis.

References:

- 1- Al-khtoum N, Shawakfeh N, Al-safadi E, Al-momani O, Hamasha K.[2013]. Acquired unilateral vocal fold paralysis: retrospective analysis of a single institutional experience. *North Am J Med Sci*5(12):699-702 .
- 2- Bando H, Nishio T, Bamba H, Uno T, Hisa Y. [2006]. Vocal fold paralysis as a sign of chest diseases a 15 year retrospective study. *World J Surg.* 30 (3) :293-8.
- 3- Barnett GC, Smith IE, Well FC, Shneerson JM. [2005]. Vocal fold palsy due to Plombage for tuberculosis: Clinical report. *J Laryngol Otol.* 119:138-9.
- 4- Chang MH, Wang CP, Anliu S.[2008]. Prognostic indicators of unilateral vocal fold paralysis. *Arch Otolaryngol Head Neck Surg.* 134(4):380-8.
- 5- Chen H C, Pei Y C, Fang T J. [2019]. Risk factors for thyroid surgery-related to unilateral vocal fold paralysis. *Laryngoscope.* 129: 275-83.
- 6- Cohen MC, Mehta DK, Maguire RC, Simons JP.[2011]. Injection medialization laryngoplasty in children. *Arch Otolaryngol Head Neck Surg.*137 (3):264-8.
- 7- Collaso-clavell ML, Gharib H, Maragos NE.[1995]. Relationship between vocal cord paralysis and benign thyroid disease. *J Head Neck Surg.*17:24-30.
- 8- Daya H, Hosni A, Bejar-solar I, Evans JN, Bailey CM.[2000]. Paediatric vocal fold paralysis: Along term retrospective study. *Arch Otolaryngol Head Neck Surg.*126:21-5.
- 9- Dikici O, Bayar Muluk N.[2013]. Left vocal cord paralysis due to lymphadenopathy of mediastinal tuberculosis. *J Med Update.* 3;(2):98-100.
- 10- Dursun G, Sataloff R, Spiegel J, Mandal S, Hemer R, Rosen D.[1996]. Superior laryngeal nerve paresis and paralysis. *J Voice.*10:206-
- 11- Friendman AD, Burns JA, Heeton JI, Zeitels SM. [2010]. Early versus late injection Medicalization for unilateral vocal cord paralysis. *Laryngoscope.* 120(10):2042-6.
- 12- Gupta J, Varshney S, Bhagat S.[2013]. Clinico-Etiological study of vocal cord paralysis. *Indian J Otolaryngol Head Neck Surg.* 65 (1) 16-19.
- 13- Howard D.[1997]. Neurological affections of the pharynx and larynx. In: John Hibbert (eds). *Scott-Brown's Otolaryngology Head Neck surgery*(6th ed). Butterworth Heinemann, Oxford, 5/9/1-20.16
- 14- Hughes RGM, Morrison M.[2005]. Vocal cord medialization by transcutaneous injection of calcium hydroxylapatite. *J Voice.*19:674-82
- 15- Jayanthi P , Menon JR.[2011]. Unilateral vocal fold palsy: An etiological study. *I J O P L.* 1(1):1-5. 16- Kayanagi K, Iga Iwabu J.[2015]. Recurrent laryngeal nerve paralysis after esophagectomy-Respiratory complications and role of nerve reconstruction. *Tohoku J Exp Med.* 237:1-8 .
- 17- Ko HC, Lee LA, Li HY, Fag T.[2009]. Etiological features in patients with unilateral vocal fold paralysis in Taiwan. *Chang Gung Med J.* 32(3):290-6.
- 18- Matsson P, Hydman J, Svensson M.[2015]. Recovery of laryngeal function after intraoperative injury to recurrent laryngeal nerve. *Gland Surg.* 4(1):27-35.
- 19- Meral M, Akgun S, Kaynar H, Mirici A, Gorguner M, Saglam L, et al.[2004]. Mediastinal lymphadenopathy due to mycobacterial infection. *Jpn J Infect Dis.* 57:124-6.
- 20- Myssonrek D.[2004]. Recurrent laryngeal nerves paralysis: Anatomy etiology. *Otolaryngol Clin North Am* (37):25-44.
- 21- Papaleontiou M, Hughes D T, Guo C, Banargie M, Haymart M R.[2017] Population based assessment of complications following surgery for thyroid cancer. *J Clinical endocrinal Metab.* 102:2543-61.
- 22- Paquette CM, Manos DS, Psooy BJ.[2012]. Unilateral vocal cord paralysis: A review of CT findings, mediastinal causes, and the course of recurrent laryngeal nerve. *Radiographics.* 32:721-40.
- 23- Phelan E, Schneider R, Lorenz K, Dralle H, Kamani D, Potenza A, et al.[2014]. Continuous vagal IONM prevents recurrent laryngeal nerve paralysis by revealing initial EMG changes of impending neuropraxic injury: a prospective, multicenter study. *Laryngoscope.*124(6):1498-505.
- 24- Rafay MA.[2000]. Tuberculosis lymphadenopathy of superior mediastinum causing vocal cord paralysis. *Ann Thorac Surg.* 70:2142-3.
- 25- Rajasekaran V, Srividhya G. [2017]. A clinical study on laryngeal manifestations of tuberculosis. *Inter J Otolaryngol Head Neck Surg;* 3(4): 845-8.
- 26- Robinson S, Pitkaranta A.[2006]. Radiological findings in adult patients with vocal fold paralysis. *Clin Radio.* 61:863-7.
- 27- Rosenthal LH, Benninger MS, Deeb RH.[2007]. Vocal fold immobility, a longitudinal analysis of etiology over 20 years. *Laryngoscope.* 117(10):1864-70.
- 28- Ryu S, Nam SY, Han MW, Choi S H, Kim SY, Roh JL.[2012]. Long-term voice outcomes after thyroplasty for unilateral vocal fold paralysis. *Arch Otolaryngol Head Neck Surg.*138-(4):347-51.
- 29- Sapundzhiev N, Lichtenberger G, Eckel HL, Friedrich G, Zenev I, Toohill RJ, et al.[2008]. Surgery of adult bilateral vocal fold paralysis in addition: History and trend. *Eur Arch Otorhinolaryngol.* 265: 1501-14.
- 30- Senniappan S, Gopalakrishnan G K, Kumar C S, Panicker A M, Nair V K, Radhakrishnan S.[2019]. Clinicoetiological profile of vocal cord paralysis. *Bengal J Otolaryngol Head Neck Surg.*27(3): 229-34
- 31- Srirompotong S, Sae-Seow P, Srirompotong S.[2001]. The cause and evaluation of unilateral vocal cord paralysis. *J Med Assoc Thai.* 84:855-8.
- 32- Varghese BT, Sebastian P, Divya GM.[2012]. An usual cause for cord palsy: Case record. *I J O P L.*2(2):88-90.
- 33- Urguhart AC, Luis ES.[2005]. Idiopathic vocal cord palsies and associated neurological conditions. *Arch Otolaryngol Head Neck Surg.*131(12) 1086-9.
- 34- Yoskovitch A, EnepeKides DJ, Hier MP. Black MG.[2000]; Guillain Barre syndrome presenting as bilateral vocal cord paralysis. *OtoLaryngol Head Neck Surg.* 122:269-70 and dysphagia. *J Laryngol Otol.* 115:422-4.
- 35- Yumoto E, Minoda R, Hyodo M, Yamagata T.[2002]. Causes of recurrent laryngeal nerve paralysis. *Auris Nasus Larynx.* 29:41-5
- 36- Zhao X, Roth K, Fung K.[2010]. Type 1 thyroplasty: Risk stratification approach. *J Otolaryngol Head and Neck Surg.*39:757-61 37. WHO Global T.B. Report (2018).

شلل الوتر الصوتي أحادي الجانب عند البالغين: العوامل المسببة- في اليمن

علي عبيد مثنى

الملخص

شلل الوتر الصوتي أحادي الجانب يقابل كثيرا بين مرضى الأذن والأنف والحنجرة. ويعد علامة لأمراض متعددة وله أسباب عدة في بعض الأحيان حيث يصعب معرفة السبب. رمت هذه الدراسة الى معرفة أسباب شلل الوتر الصوتي أحادي الجانب بين البالغين. أجريت هذه الدراسة المستقبلية الوصفية بقسم الأذن والأنف والحنجرة بمشفى الثورة التعليمي - صنعاء - اليمن. خلال الفترة بينايز 2016 إلى يونيو 2018 وقد شملت 80 مريضا يعانون من شلل أحد الأوتار الصوتية. أظهرت نتائج الدراسة أن نسبة الذكور كانت (73.6%) والإناث (26.4%) وتراوحت أعمارهم بين 18-80 سنة. الوتر الصوتي الأيسر كان أكثر تأثرا بنسبه (93,6%). وجد أن السبب غير المعروف يمثل (32,5%)، الأورام الخبيثة (31,2%)، الإصابات (21,3%)، وكانت نسبة عمليات الغدة الدرقية أكثرها (41,2%). السل الرئوي (7,5%)، أسباب مركزية (6,3%). أكثر الأسباب التي تؤدي لشلل الحبل الصوتي أحادي الجانب غير معروف، الأورام الخبيثة تأتي في المرتبة الثانية والإصابات الجراحية وغير الجراحية في المرتبة الثالثة. عمليات الغدة الدرقية تمثل أعلى الإصابات التي تؤدي إلى شلل الحبل الصوتي. لذلك يجب إجراء تنظيف للحنجرة قبل وبعد عملية الغدة الدرقية لخفض نسبة الإصابة بشلل الوتر الصوتي أحادي الجانب.

الكلمات المفتاحية : شلل الحبل الصوتي أحادي الجانب، العصب الحنجري الراجع، أسباب. المرضى البالغين، اليمن.